



The Mitigating Effects of *Annona muricata* (Linn) Ethanol Leaf Extract on Melamine-induced Nephrotoxicity in Male Rats

Ajayi, A. A. and Ijeh, I. I.

Department of Biochemistry, College of Natural Science, Michael Okpara University of Agriculture, Umudike, Nigeria.

Abstract: The mitigating effects (biochemical and histological) of *Annona muricata* (Soursop) ethanol leaf extract in melamine-induced nephrotoxicity were evaluated in male albino rats. Forty Wistar rats aged 8-10 weeks old were randomly distributed into Groups A to E (n=8). Group A (vehicle control) received 7 ml/kg body weight (b.w) of 10% Tween-80, Groups B to E were administered 1000 mg/kg b.w of melamine for 10 days. After 10 days of melamine induction, Group C was administered the reference drug, allopurinol (100 mg/kg b.w), Groups D and E were treated with 300 and 500 mg/kg b.w of ethanol extract respectively. Groups C to E were sacrificed on day 22. Secondary metabolite analysis of the ethanol extract gave flavonoids (120 mg/g) as the highest. The oral acute toxicity test gave zero mortality up to 5000 mg/kg b.w of ethanol extract. Treatment with ethanol leaf extracts (300 mg/kg b.w) caused a significant ($P<0.05$) decrease in serum creatinine, urea, calcium and magnesium whereas the extract at 500 mg/kg b.w only resulted in significant ($P<0.05$) decrease in creatinine when compared to the animals that received melamine only. The histology of the kidneys of melamine-induced nephrotoxic rats administered 300 mg/kg b.w of ethanol extract were characterized by moderate tubular dilation, increased secretions in the tubules and few collapsed vessels compared with persistent dilations and occlusion in those induced with melamine only. The findings from this study suggest that at low dose, leaf extract of *A. muricata* could be effective for the treatment of melamine-induced nephrotoxicity in rats.

KEYWORDS: Allopurinol, *Annona muricata*, Melamine, Nephrotoxicity

1.0 Introduction

Melamine (1,3,5-Triazine-2,4,6-Triamine, also called cyanurotriamide, cyanuramide) is a white solid organic nitrogenous compound used in the production of plastics, dyes, fertilizers, and fabrics. Nephrotoxicity of melamine in dogs and cats have been reported in North America (Burns, 2007). In China, however, melamine contamination scandal led to the outbreak of urinary stones in children that consumed melamine-tainted milk (Bhalla *et al.*, 2009; WHO, 2009). A variety of toxic effects could arise from unwitting level of melamine exposure in food and other home used products. Such toxic effects are nephrolithiasis, chronic kidney inflammation, bladder carcinoma and urinary bladder stone, which have been studied in animals (Hau *et al.*, 2009). These toxicities have prompted the increasing quest for remedy and

the rising tendency for individuals to result to self-help with the aim of averting or mitigating the untoward consequences of the diseases.

Annona muricata may have been reported to have antiarthritic, antinociceptive, anti-hyperglycemic, and anticancer activities in laboratory experiments (Jaramillo *et al.*, 2000; De Sousa *et al.*, 2010). Since *A. muricata* has been reported from various studies to possess different medicinal values, therefore, there is need to investigate its renoprotective effects on the challenged kidneys of adult Wistar rats.

2.0 Materials and Methods

2.1 Materials

2.1.1 Plant material

Fresh leaf of *A. muricata* was collected randomly from Afikpo, Afikpo-North LGA of Ebonyi State, Nigeria. The leaf was authenticated by Mr. K.K Ibe, a plant

*Corresponding Author

Tel.: +234 7034205898

E-mail: ifeoma@mouau.edu.ng

taxonomist in the Forestry Department of Michael Okpara University of Agriculture, Umudike, Abia State, Nigeria, with voucher number Jones FHI6337. The specimen was kept for future references in the herbarium of Forestry Department.

2.1.2 Experimental animals

Forty Wistar rats used in this study were obtained from University of Nigeria, Nsukka, Nigeria.

2.1.3 Chemicals

All chemicals and reagents used were of analytical grade.

2.2 Methods

2.2.1 Plant preparation

A known amount (60 g) of the powdered leaf sample was macerated in a stoppered container with 800 ml of ethanol added and left at 25^oC for 72 hours with frequent agitation. The mixture was then strained using cheese cloth, the marc (the damp solid material) was pressed, and the mixture was then filtered using Whatmann filter paper No. 42 (125 mm). The filtrate was left on laboratory bench to evaporate to dryness. The percentage yield of crude extract was calculated according to Cowan (1999).

2.2.2 Animal Studies

The animals used for the study were healthy albino rats aged 8-10 weeks old, housed at 25-28^oC and 12 hours light and dark cycle, maintained on rat feed *ad libitum* and acclimatized for two weeks. The study was conducted in line with internationally acceptable principles for laboratory animal use and care of OECD (2000).

2.2.3 Induction of melamine nephrotoxicity and treatments

Forty Wistar rats were randomly distributed into Groups A to E (n=8). Group A (vehicle control) received 7 ml/kg b.w of 10% Tween-80,

Groups B to E were administered 1000 mg/kg b.w of melamine for 10 days. Treatments with extract and reference drug were done sequentially after confirmation of toxicity. Group C was administered 100 mg/kg b.w of allopurinol (reference drug). Animals in Groups A and B were sacrificed on day 11 while those in groups C, D and E were sacrificed on day 22.

2.2.4 Determination of Secondary metabolite studies

Determination of secondary metabolites was carried out on the extract; flavonoids and alkaloids were determined as described by Harborne (1973). Determination of reducing sugars was carried out by the method of Miller (1972), saponins and cyanogenic glycosides were estimated by the method outlined in AOAC (2010). Determination of tannin was done using colorimetric method of van-Buren and Robinson, (1981). Phytates were determined by the procedure of Lucas and Markakas (1975) while oxalate content was determined using the method of Sanchez-Alonso and Lachia (1987).

2.2.5 Acute toxicity studies

Acute toxicity study was carried out according to the method of Lorke (1983). The test was conducted in two phases with 12 rats in each phase. In phase I, three groups of three rats per group were administered the extract at 10, 100 and 1000mg/kg b.w. The fourth group was used as control and administered 10% Tween-80 (the solvent used to dissolve the extracts). The rats were closely monitored for behavioural changes and mortality within 24 hours. Phase II consisted of rats grouped as in phase I but groups 1, 2 and 3 were respectively administered doses of 1600, 2900 and 5000 mg/kg body weight of the extract. The animals were closely observed for 24, 48, 72 hours and 2 weeks for possible behavioural changes and mortality.

2.2.6 Analysis of non-protein nitrogenous (NPN) substances and electrolytes

Blood samples were obtained from the rats and the serum were used to assay for NPN (creatinine, uric acid, urea) and electrolytes

(calcium, sodium, potassium, magnesium) colorimetrically using Randox kits (Randox Laboratories Ltd, UK) and TECO kits (TECO diagnostics Lakeview, Avenue, USA).

2.2.7 Renal histology

The left and right kidneys were excised from the animals. The kidneys were placed in sample bottles containing absolute ethanol (Stine *et al.*, 2014) and prepared for histological examination. The photomicrographs capturing of the kidneys was done within 72 hours of removal. Wet-mount procedure was carried out according to the method of Clayden, (1967) and John and Alan, (1977). Slices of the kidney were fixed in absolute alcohol for 48 hours. The specimens were processed by placing them in ascending grades of alcohol to dehydrate the tissues. Mixture of alcohol and xylene were also used overnight on the slices and infiltrated with paraffin wax before sectioning. Excess wax was removed with xylene and slides stained by infiltrated haematoxylin, washed in water and then alcohol. Slides were counterstained with eosin and removed with grades of alcohol and xylene. The slides were viewed under a light microscope at x400 and selected images were captured using Moticam 2.0 digital camera attached to a computer.

2.2.8 Statistical analysis

The data on phytochemical analysis were obtained in duplicate and presented as mean \pm SEM. SPSS software (version 17.0; International Business Machines Corporation, IBM) was used to analyze data from biochemical analyses using one way ANOVA. LSD (*Post hoc* Test) was used to obtain the descriptive and multiple comparisons. The differences between means were taken to be significant at $P < 0.05$.

3.0 Results

The ethanol extract contained in the order flavonoids > alkaloids > saponins > cyanogenic glycosides > tannins > phytate > oxalate > reducing sugars as shown in Table 1.

The extract when administered for 24 hours, 48 hours and 2 weeks showed no obvious sign of toxicity, since no behavioural changes or death were recorded.

Administration of 300 and 500 mg/kg b.w of the extract to melamine-induced nephrotoxic rats in groups D and E resulted in a significant ($p < 0.05$) decrease in creatinine concentration compared with the negative control that received 1000mg/kg b.w only (Figure 1). Treatments of the animals in groups D and E with 300 and 500 mg/kg b.w of extract showed a non-significant ($p > 0.05$) decrease and increase respectively in the concentration of uric acid when compared with melamine-induced nephrotoxic rats that were administered 1000 mg/kg b.w of melamine (Figure 2). The concentration of urea in melamine-induced nephrotoxic animals of groups D and E were significantly ($p < 0.05$) reduced when compared with the negative control. The concentration of calcium (Figure 4) and magnesium ions (Figure 7) for animals in group D that received 300 mg/kg b.w of extract were significantly ($p < 0.05$) decreased when compared with the negative control. Administration of the extract to animals in groups D and E caused a non-significant ($p < 0.05$) decrease in sodium ion concentration when compared with the negative control while a non-significant increase was observed in the concentration of potassium ion after the administration of the extract to animals in groups D and E.

The results of histology carried out on kidney of selected rats in groups A-E at different doses of administrations of the extract and drugs is shown in Plates 1a-e indicating features such as mesangium (M), glomerulus (G), and tubule (T). Photomicrograph of the kidneys of the rats gave different degrees of clinical presentation ranging from no significant pathology, crystals/ stone formations, dilated tubules, secretions to collapse vessels etc. Animals in group A (Plate 1a) showed normal viable tubular epithelium and no clinical pathology when compared with those in group B (Plate 1b) which showed dilated tubules and increased luminal eosinophilic secretions in the tubules. The dilation of tubules were compatible with distal obstruction due to crystals or renal stone as a result following the administration of

Table 1: Secondary metabolite constituents of ethanol leaf extracts of *A. muricata* (mg/g dry weight)

Phytochemical	Concentration (mg/g)
Flavonoids	120.0 ± 30.0
Alkaloids	90.0 ± 10.0
Saponins	5.10 ± 0.30
Tannins	1.36 ± 0.17
Reducing sugars	0.025 ± 0.13
Cyanogenic glycosides	1.62 ± 0.32
Phytates	0.99 ± 0.29
Oxalates	0.77 ± 0.11

Data obtained were determined in duplicate and presented as Mean ± SEM on dry weight basis

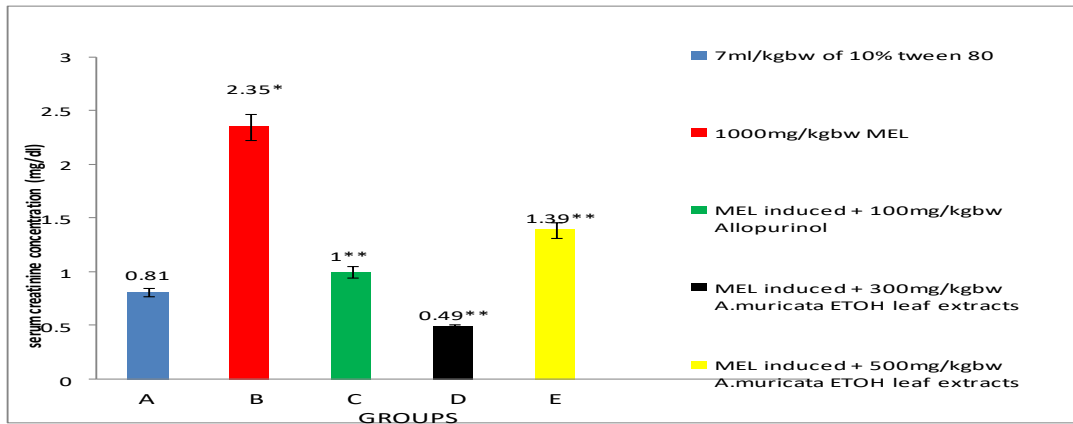


Figure 1: Effects of *Annona muricata* ethanol leaf extract on serum creatinine concentration of melamine-induced nephrotoxic rats

*P<0.05 compared with Group A, **P<0.05 compared with Group B

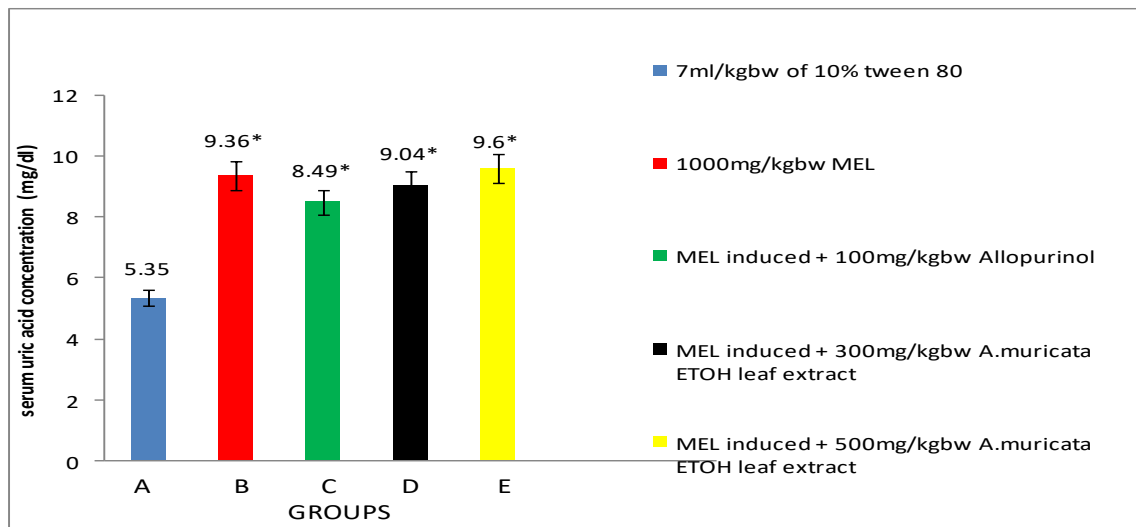


Figure 2: Effects of *Annona muricata* ethanol leaf extract on serum uric acid concentration of melamine-induced nephrotoxic rats

*P<0.05 compared with Group A

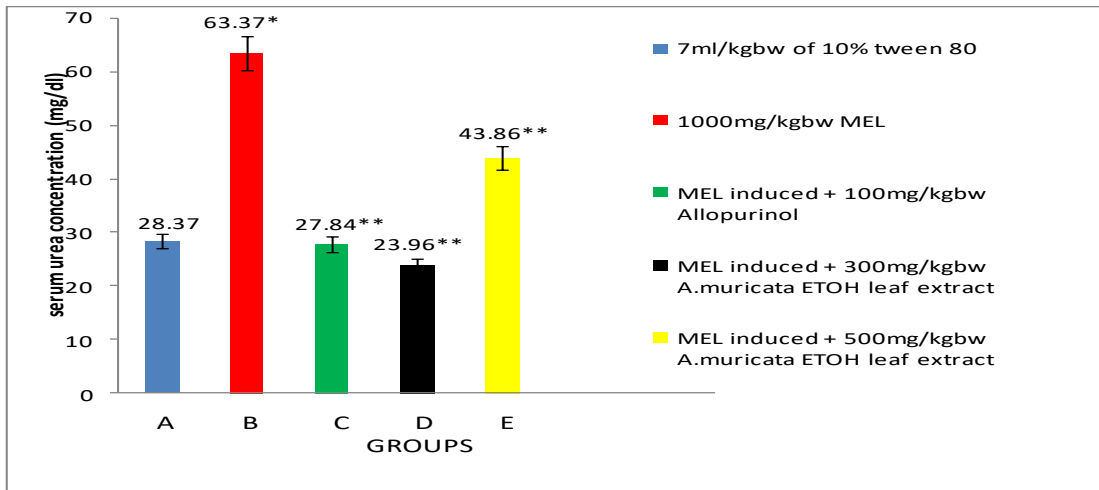


Figure 3: Effects of *Annona muricata* ethanol leaf extract on serum urea concentration of melamine-induced nephrotoxic rats

*P<0.05 compared with Group A, ** P< 0.05 compared with Group B

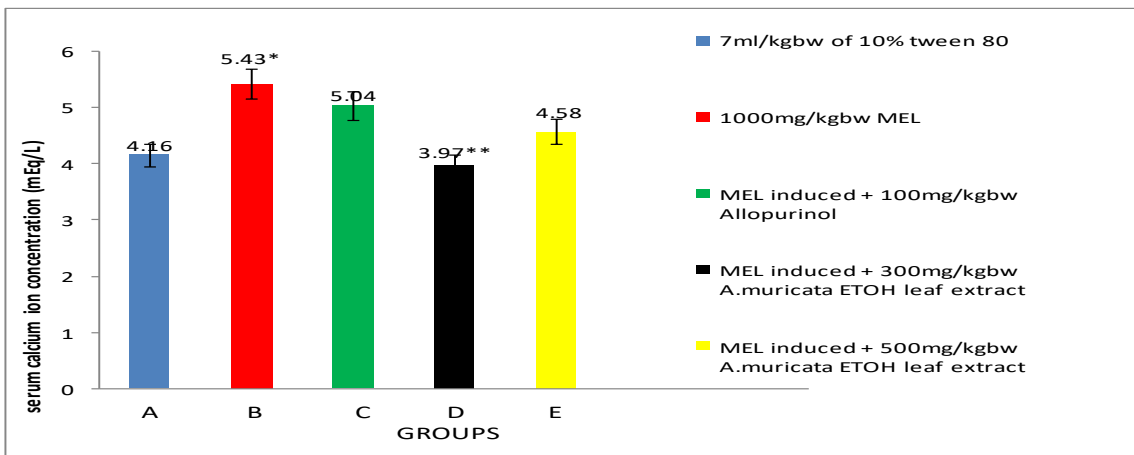


Figure 4: Effects of *Annona muricata* ethanol leaf extract on serum calcium ion concentration of melamine-induced nephrotoxic rats

*P<0.05 compared with Group A, ** P< 0.05 compared with Group B

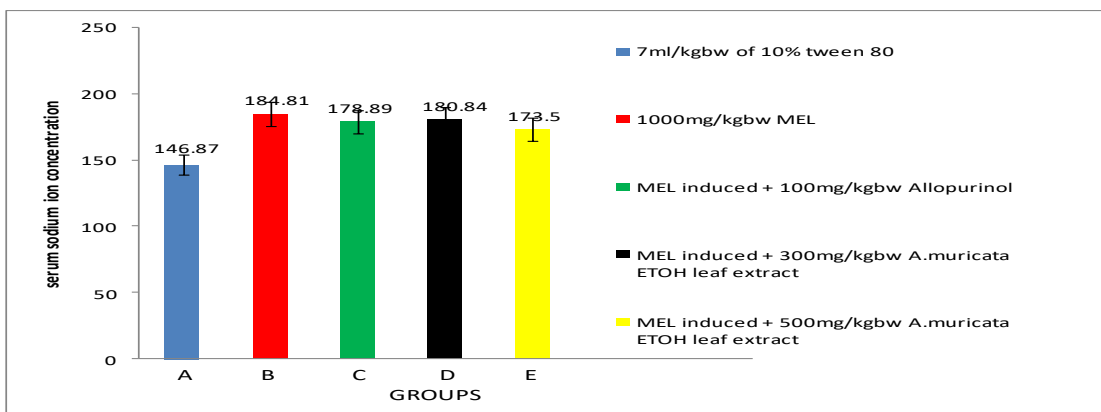


Figure 5: Effects of *Annona muricata* ethanol leaf extract on serum sodium ion concentration of melamine-induced nephrotoxic rats

*P<0.05 compared with Group A

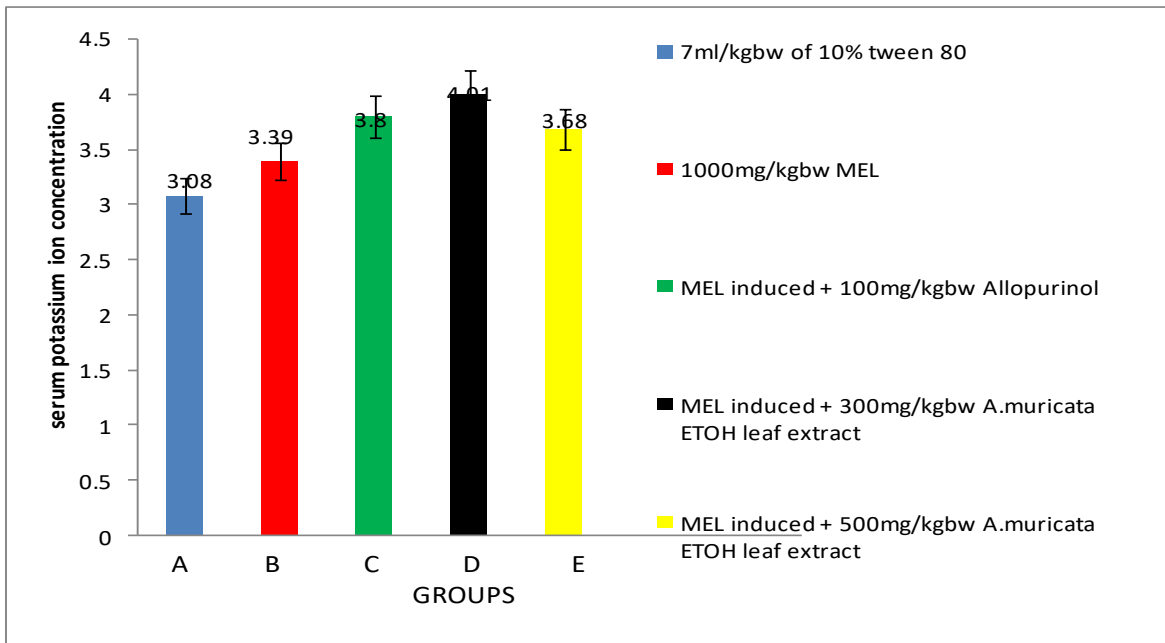


Figure 6: Effects of *Annona muricata* ethanol leaf extract on serum potassium ion concentration of melamine-induced nephrotoxic rats

*P<0.05 compared with Group A, ** P< 0.05 compared with Group B

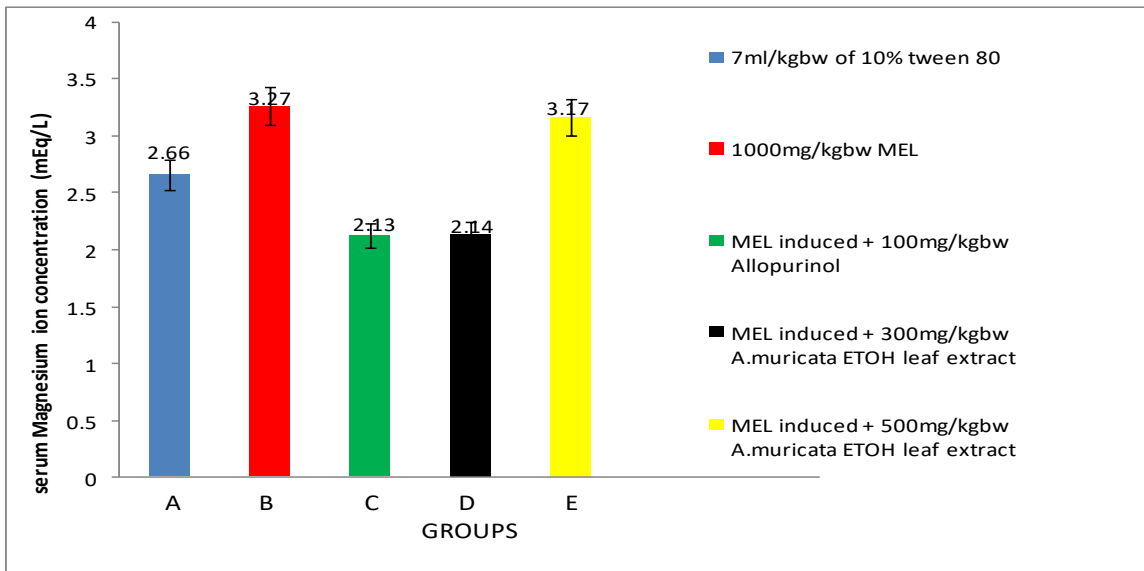


Figure 7: Effects of *Annona muricata* ethanol leaf extract on serum magnesium ion concentration of melamine induced albino rats

*P<0.05 compared with Group A, ** P< 0.05 compared with Group B

1000 mg/kg b.w of melamine. Animals in group C (Plate 1c) treated with reference drug caused a progression from persistent tubular dilation and few collapse vessels to a state free of clinical pathology after treatments when compared with the negative control. Group D (Plate 1d) rats administered 300 mg/kg b.w of extract resulted in moderate dilation of the tubules with

increased tubular secretion of eosinophilic material and glomeruli having few collapsed vessels while those in Group E (Plate 1e) resulted in persistent dilation of the tubules with the glomeruli having many collapsed vessels after 11days treatment when compared with those of Group B (Plate 1b).

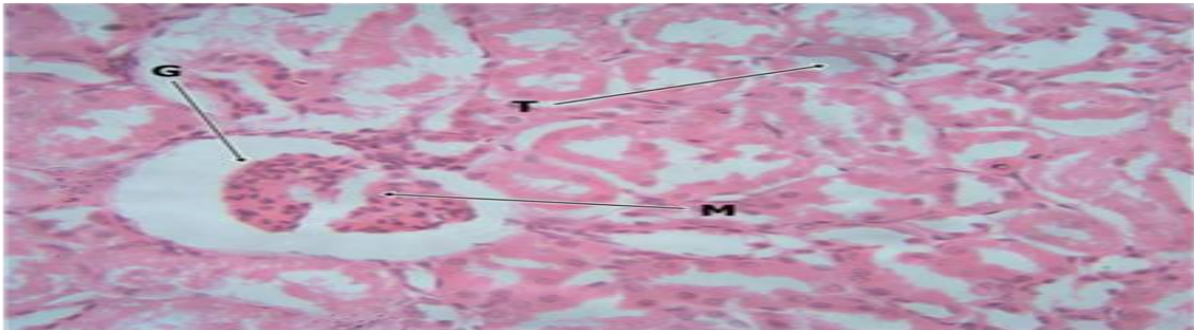


Plate 1a: Cross section of rat kidney administered 10% Tween 80 (H & E; x400)

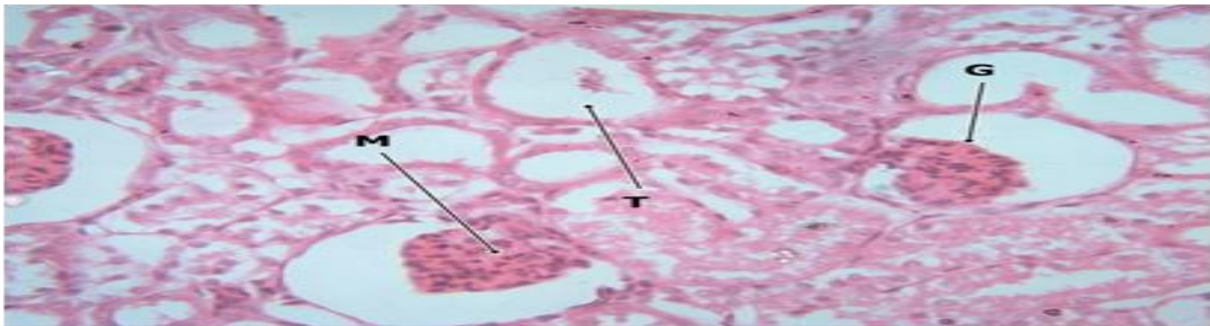


Plate 1b: Cross section of rat kidney administered melamine (H & E; x400)

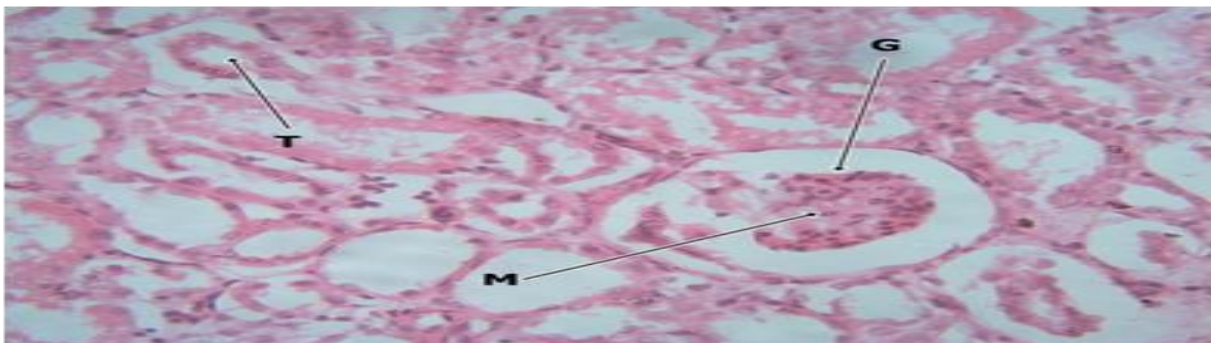


Plate 1c: Cross section of kidney of rat treated with melamine and administered allopurinol (H & E; x400)

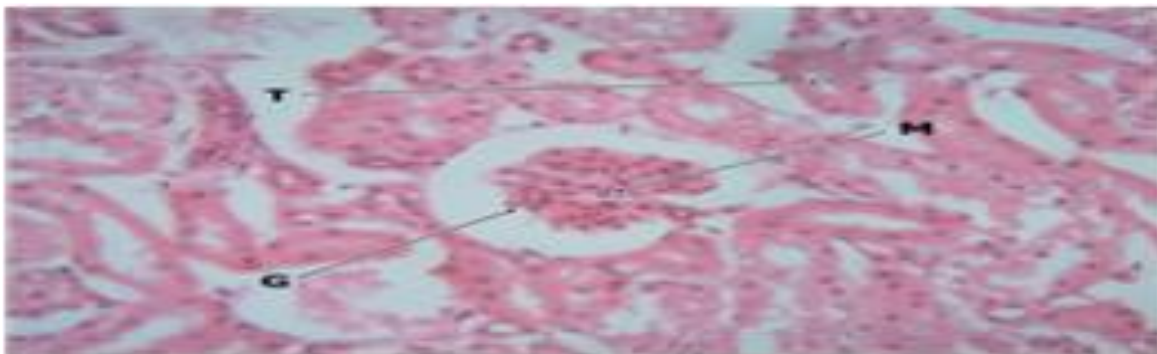


Plate 1d: Cross section of kidney of rat treated with melanine and administered 300 mg/kgbw of ethanol extract of *A. muricata* leaf (H & E; x400)

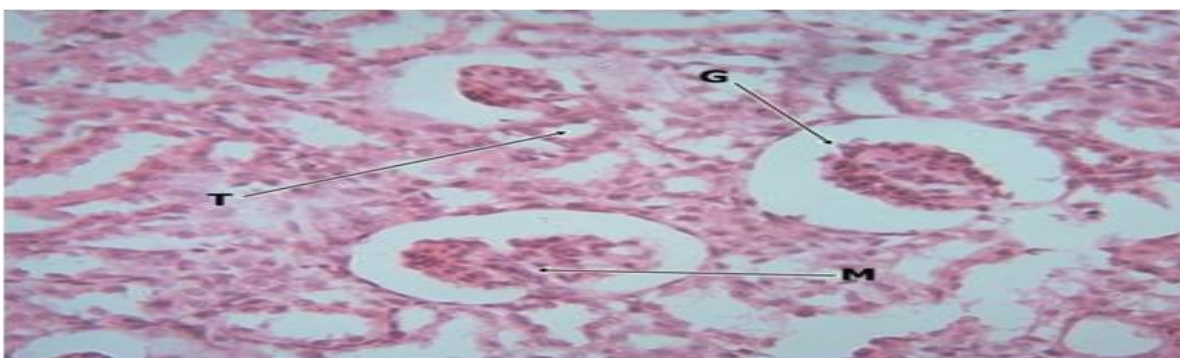


Plate 1e: Cross section of kidney of rat treated with melanine and administered 500 mg/kg b.w of ethanol extract of *A. muricata* leaf (H & E; x 400)

Discussion

The secondary metabolite analysis of ethanol extract of *A. muricata* leaf showed that flavonoids were the highest (120 mg/g) of all the compounds determined. This value is higher than that reported by Akinseye *et al.*, (2016) for water leaf extract of the same plant. The most prevalent phenol from plants are flavonoids (Balasundram *et al.*, 2006) exhibiting effects on allergy, oxidative stress and inflammation. They are useful as antimicrobials, antitumour, antitoxins (Benavente-Garcia and Castillo, 2008).

Alkaloids contents was 90 mg/g and higher than that reported by Shibula and Velavan, (2016) for 70% methanol extract of *A. muricata*. Alkaloids are responsible for analgesic properties found in medicinal plants (Ojezele *et al.*, 2016). Saponin content obtained was lower

than that reported by Akinseye *et al.*, (2016) for water leaf extract of *A. muricata*. Saponins are capable of inhibiting histamine release *in vitro*, possess membrane permeability properties and lead to vacuolization and disintegration of teguments (Prashant *et al.*, 2011). Tannins have exhibited antimicrobial properties interfering with endogenous microbial protein synthesis depriving microbes of protein utilization (Ncube *et al.*, 2008; Adeosun *et al.*, 2016). The anti-nutrients determined were cyanogenic glycosides, phytate, and oxalate. Phytate content was higher than that reported by Fasakin *et al* (2008) for the seed of *A. muricata* and oxalate have the tendencies to complex with some minerals (calcium, magnesium, iron etc) making them unavailable for the body system metabolisms and utilization (Golam, *et al.*, 2011). Therefore, phytate could be inadvertently useful in the treatment of kidney stone.

The acute toxicity test showed that the dose capable of causing mortality or morbidity to the rats is > 5000mg/kg b.w. Therefore, the extracts may be considered safe at less than 5000mg/kg b.w. This finding agrees with study reported by Larbie *et al.*, (2011) for *A. muricata*. This forms the basis for the selected doses because the highest treatment dose was not greater than one-tenth of 5000 mg/kg b.w. in accordance with OECD (2000).

Administration of 1000 mg/kg b.w of melamine to rats resulted in elevated serum NPN and selected electrolytes level compared to those administered 10% Tween-80, those induced but treated with allopurinol and *A. muricata* extracts. These outcomes agree with increase in NPN reported by Stine *et al.* (2014) due to melamine induction in rats. Melamine induction form crystals and cause pathological effects as shown in the kidney histology with dilated tubules compatibles with occluded crystals or stone formation in the kidneys, preventing normal excretion and accumulation of NPN and electrolytes.

The administration of the extracts to melamine treated rats resulted in a dose-dependent increase in creatinine, urea and uric acid concentrations. A significant decrease was observed in creatinine and urea at the 300 mg/kg bw of ethanol extract. The reductions in urea and creatinine levels corroborate the study reported by Syahida *et al.* (2012). It could also have diuretic activity which enhances the elimination of urea and creatinine through increase in urine production via the renal tubule (Yadav *et al.*, 2011). However, the effect on uric acid reduction was low which may explain why it is the mediator of kidney stone formation in melamine ingestion (Zhang *et al.*, 2015). The occlusion of the renal tubules could have occurred at the site of secretion of uric acid in the tubules preventing its elimination. This is further evident from histological examination of the kidney that showed tubular dilations resulting from crystal depositions.

The finding with respect to elevated electrolytes arising from melamine administration agrees with the study reported by ElRabey *et al.* (2013) on the effects of melamine ingestion. However, the administration of 300 mg/kg b.w of extract caused a significant

reduction in calcium and magnesium ion concentrations. The reduction in electrolytes agree with the study reported by Gumaih *et al.* (2007) who reported significant decrease in electrolytes in ethylene glycol- induced rats treated with parsley extract. These reductions in the levels of calcium and magnesium ion may be due to the presence of phytates in the extract. Phytates have the tendency to complex excess calcium and magnesium ions in the blood preventing its accumulation in the body (Akande *et al.*, 2010; Agbaire and Emoyan, 2012). But sodium and potassium ion concentrations slightly decreased and increased respectively compared to animals that were administered melamine only. This outcome was in line with the study reported by Akpanabiatu *et al.*, (2005) on effects of *Nauclea latifolia* extract on sodium and potassium levels in rats. The extracts, in the present study, could not restore the elevated level of these ions possibly because occlusion occurred at the sites of secretion/elimination of ions. This could create an imbalance and an increase in reabsorption of sodium and potassium ions in the distal tubules and proximal convoluted tubules respectively (Vasudevan *et al.*, 2011; Palmer, 2014).

The histological examination of the kidneys revealed that the administration of 300 mg/kg bw extract used to treat melamine toxicity gave moderate dilations with few collapsed vessels but at 500 mg/kg bw., the dilations were persistent with many collapsed vessels. These outcomes agreed with the study reported by Ezejindu *et al.* (2014) on *A. muricata*, that at high dose, the extract caused adverse effects on kidney cells but at low dose enhances the elimination of accumulated substances.

Furhtermore, the selected renal function parameters and histological examinations revealed various pathological presentations due to melamine administration in rats which can be used as a basis for treatments for melamine toxicity. Also, this study has shed light and created more awareness on the inherent bioactive constituents and possible medicinal importance of *A. muricata*.

However, the present study suffers some limitations. The inability to capture the crystals from the renal examination is a constraint due to the use of light microscope, whereas an electron

microscope would have been suitable for that purpose. Another limitation of this study is that hormones that regulate electrolytes were not assayed for and could have been useful in providing a better insight into the study. The glomerular filtration rate and renal clearance test involving both male and female rats could be done to further extend the study.

Conclusion

The study concluded that the leaf extract ameliorated the toxic effects of melamine on renal tissues thus restoring normal renal functions.

References

- Adeosun, A. M., Oni, S. O. Ighodaro, O. M., Durosinslorun, O. H. and Oyedele, O. M. (2016). Phytochemical, minerals and free radical scavenging profiles of *Phoenix dactylifera* L. seed extract. 12(11): 1595-1653. Journal of Taibah University Medical Sciences 11(1):1-6.
- Agbaire, P. O. and Emoyan, O. O. (2012). Nutritional and antinutritional levels of some local vegetables from Delta State, Nigeria. African Journal of Food Science 6(1): 8-11.
- Akande, K. E., Doma, U. D., Agu, H. O. and Adamu, H. M. (2010). Major antinutrients found in plant protein sources: Their effect on nutrition. Pakistan Journal of Nutrition 8:827-832.
- Akinseye, O.R., Morayo, A.E., and Akinwale, S.O (2016). Phytochemical evaluation of dry, wet and oil of leaf of *Annona muricata* for medical activities. Journal of Pharmacy and Alternative Medicine 13:42-47.
- Akpanabiatu, N. I., Umoh, I. B., Udosen, E. O., Udoh, A. E and Edet, E. E. (2005). Rat serum electrolytes, lipid profile and cardiovascular activity on *Nauclea latifolia* leaf extract administration. Indian Journal of Clinical Biochemistry 20 (2):29-34.
- AOAC (2010). Official Methods of Analysis. Association of Official Analytical Chemists, 15th Edn., Washington D.C., USA.
- Balasundram, N., Sundram, K. and Samman, S. (2006). Phenolic compounds in plants and agri-industrial by-products: Antioxidant activity, occurrence and. potential uses. Food Chemistry 99(1):191-203.
- Benavente-Garcia, O. and Castillo, J. (2008) Update on and properties of citrus flavonoids: New findings in anticancer, cardiovascular and anti-inflammatory activity. Journal of Agricultural and Food Chemistry 56(15): 6185-6205.
- Bhalla, V., Grimm, P. C., Chertow, G. M. and Pao, A. C. (2009). Melamine nephrotoxicity: an emerging epidemic in an era of globalization. Kidney International 75:774-779.
- Burns, K. (2007). Researchers examine contaminants in food, deaths of pets: Survey, case definition, studies implicate combination of melamine and cyanuric acid. Journal of American Veterinary Medical Association 231:1632-1644.
- Clayden, E. (1967) Practical section cutting and staining 4th Ed. J.E. Church Hill Ltd. pp. 87.
- Cowan, M. M (1999). Plant products as antimicrobial agents. Clinical Microbiology Reviews 12(4): 564-582.
- De Sousa, O. V., Vieira G. D., De Jesus, R. G., De Pinho, J., Yamamoto, C. H and Alves, M. S. (2010). "Antinociceptive and Anti-Inflammatory Activities of the Ethanol Extract of *Annona muricata* L. Leaves in Animal Models". International Journal of Molecular Sciences, 11(5):2067-2078.
- EL Rabey, H. A., AL-sieni, A. I., and Majami, A. A (2013). The toxic effect of melamine on the kidney of male rats as revealed by biochemical and histopathological investigations. Life science Journal 10(1):950-963.
- Ezejindu, D. N., Udemezue, O. O., Chukwujekwu, I. E., Uchefuna, R. C., Maduka, S. O., Akingboye, A. J and Ezejindu, C. N. (2014). The histological effects of *A. muricata* ethanol leaf extract on the kidneys of adult waster Rats. International Journal of Research in Medical and Health Sciences 4(6): 2307-2083.
- Fasakin, A. O., Fehintola, E. O., Obijole, O. A., Oseni, O. A. (2008). Compositional analyses of the seed of sour sop, *Annona muricata* L., as a potential animal feed supplement. Scientific Research and Essay 3(10):521-523.
- Golam, M. A., Heath, C., Janele, B., Zahirul, I. T., and Khwaja, H. (2011). Minerals (Zn, Fe, Ca and Mg) and antinutrient (phytic acid) constituents in common bean. American Journal of Food Technology 6 (3): 235-243.
- Gumaih, H., Al-yousofy, F., Ibrahim, H., Ali, S. and Alasbahi, A. (2007). Evaluation of ethanolic seed extract of parsely on ethelen glycol induced calcium oxalate, experimental model. International Journal of Science and Research 6:1683-1688.
- Harborne, J. B. (1973). Phytochemical Methods, Chapman and Hall Ltd, London. pp. 49-188.
- Hau, A. K. C., Li, P. K. T. and Kwan, T. H. (2009). Melamine toxicity and the kidney. Journal of the American Society of Nephrology 20 (2):245-250.

- Jaramillo, M., Arango, G., Gonzalez, M., Robledo, S. and Velez, I. D. (2000). Cytotoxicity and antileishmanial activity of *Annona muricata* pericarp. *Fitoterapia* 71:183-186.
- John, O. B. and Alan, S. (1977). *Theory and Living stone*. Dinburgh Publisher, London. pp. 86-108.
- Larbie, C., Terlabi, E. O., Woode, E., Arthur, F. K. N. (2011). Evaluation of acute and subchronic toxicity of *Annona muricata* (Linn) aqueous extract in animals. *European Journal of Experimental Biology* 1(4):115-124.
- Lorke, D. (1983). A new approach to practical acute toxicity testing. *Archives of Toxicology* 54:275-287.
- Lucas, G. M. and Markakas, P. (1975). Phytic acid and other phosphorus compounds of bean (*Phaseolus vulgaris*) *Journal of Agricultural Education Chemistry* 23:13-15.
- Miller, G. L. (1972). Estimation of reducing sugars by DNS method. *Analytical Chemistry* (3):426.
- Ncube, N. S., Afolayan, A. J. and Okoh, A. I. (2008). Assessment techniques of antimicrobial properties of natural compounds of plant origin: Current methods and future trends. *African Journal of Biotechnology* 7(12):1797-1806.
- OECD (2000). *Guidance Document on Acute oral toxicity*. Environmental Health and Safety Monograph Serum on Testing and Assessment. No 24.
- Ojezele, O. J., Ojezele, M.O., and Adeosun, M. A (2016). Comparative phytochemistry and antioxidant activities of water and ethanol extract of *Annona muricata* Linn leaf, seed and fruit. *Advances in Biological Research* 10(4):230-235.
- Palmer, B. F. (2010). A physiologic-based approach to the evaluation of a patient with hyperkalemia. *American Journal of Kidney Diseases* 56: 387–393.
- Prashant, T., Bimlesh, K., Mandeep, K., Gurpreet, K., and Harleen, K. (2011). Phytochemical screening and extraction: A Review. *International Pharmaceutica Scientia* (1):98-106.
- Sanchez-Alonzo, F. and Lachia, M. (1987). Seasonal trends in the elemental content of Plum Leaf. *Common Soil Science Plant Analytical*, 18:31-44.
- Shibula, K. and Velavan, S. (2016). Determination of bioactive compounds in *A. muricata* leaf extract. *Journal of Bioscience and Technology* 7(3):762-768.
- Stine, C. B., Reimschuessel, R., Keltner, Z., Nochetto, C. B. and Black, T. (2014). Reproductive toxicity in rats with crystal nephropathy following high doses of oral melamine or cyanric acid. *Food and Chemical Toxicology* 68:42-153.
- Syahida, M., Maskat, M. Y., Sur, R., Mamot, S. and Hadijah, H. (2012). Soursop (*Annona muricata*): Blood hematological and serum biochemistry of Sprague-Dawley rats. *International Food Research Journal* 19 (3):955-959.
- Van Buren, J. P. and Robinson, W. B. (1981). Formation of complexes between protein and tannic acid. *Journal of Agricultural and food Chemistr*, 1:772-777.
- Vasudevan, D. M., Sreekomari., S. and Vaidyanathan, K. (2011). *Textbook of Biochemistry for Medical Students*. 6th Ed. Jaypee Brother Medical Publishers (P) LTD. New Delhi, India. Pp. 320.
- WHO (2009). *Melamine and Cyanuric Acid: Toxicity, Preliminary Risk Assessment and Guidance on Levels in Food*. World Health Organization, Geneva.
- Yadav, R. D., Alok, S., Jain, S. K., Verma, A., Matior, A., Bharti, J. P and Jaiswal, M. (2011). Herbal plants used in treatment of urolithiasis: A Review. *International Journal of Pharmaceutical Science and Research* 2(6):1412-1420.
- Zhang, L., Hong, T., Wang, L. L., Trachtman, H., Trasaide, L., Wang, P. X. and Liu, J. M. (2015). Melamine nephrotoxicity is mediated by hyperuricemia. *Biomedical and Environmental Science* 28(12):904-912.